

Noticia Clínica

Use of Vacuum-assisted closure (VAC) for the treatment of necrotizing fasciitis from Fournier's gangrene

Uso de terapia de presión negativa en el tratamiento de Gangrena de Fournier – fascitis necrotizante

García Córdova CE, Flandes Aguilar IE, Guillen Martínez EA, Pérez Silva LA, Dominguez Castillo RE

Hospital Central Sur de Alta Especialidad Petróleos Mexicanos, México.

RESUMEN

La gangrena de Fournier es un tipo de fascitis necrotizante que afecta el área genital, se caracteriza por su inicio agudo y alta mortalidad.

El diagnóstico temprano y el tratamiento quirúrgico agresivo son cruciales para lograr los mejores resultados, generalmente se requieren múltiples desbridamientos quirúrgicos. La herida quirúrgica resultante puede curarse por segunda intención o con tratamientos adicionales.

Se presenta el caso de un paciente varón que acude a urgencias por tumefacción inguinal izquierda aguda, dolor y secreción purulenta. Después de varios desbridamientos quirúrgicos y control de la fuente infecciosa, se aplicó un dispositivo de cierre asistido por vacío (VAC) hasta lograr el cierre de la herida.

Palabras clave: Gangrena de Fournier, fascitis necrotizante, tratamiento Gangrena de Fournier, fascitis necrotizante, tratamiento.

ABSTRACT

Fournier's gangrene, a type of necrotizing fasciitis affecting the genital area, it is characterized by its acute onset and high mortality.

Early diagnosis and aggressive surgical treatment are crucial to attain the best results, multiple surgical debridements are usually required. The resulting surgical wound may be healed by secondary intention or with additional therapies.

We introduce the case of an adult male patient that presented to the emergency room with acute left inguinal swelling, pain, and purulent discharge. After several surgical debridements as well as infectious source control a vacuum-assisted closure (VAC) device was applied until wound closure was achieved.

Key words: Fournier's gangrene, necrotizing fasciitis, treatment

CORRESPONDENCIA

Ingrid Elvira Flandes Aguilar
Hospital Central Sur de Alta Especialidad Petróleos Mexicanos
14140 Ciudad de México
iflandesa@gmail.com

XREF

CITA ESTE TRABAJO

García Córdova CE, Flandes Aguilar IE, Guillen Martínez EA, Pérez-Silva LA, Dominguez Castillo RE. Use of Vacuum-assisted closure (VAC) for the treatment of necrotizing fasciitis from Fournier's gangrene. Cir Andal. 2023;34(3):400-403. DOI: 10.37351/2023343.15

INTRODUCTION

Fournier's gangrene is a type of necrotizing fasciitis which affects the perineal, and the genital area. Characterized by an acute onset, abrupt progression, and high mortality between 20-30%¹.

Vacuum-assisted closure (VAC) has been used as an aid in the closure of abdominal wounds, it has a reported rate of closure at 10 weeks and a mean survival of 90 days after the first surgery¹.

We introduce the case of an adult male, with type 2 diabetes mellitus. The patient presented to the emergency room with left inguinal swelling associated with pain, and purulent discharge. Broad spectrum antibiotic therapy was initialized, and multiple surgical debridements were made. After infectious source control a VAC device was applied by 16 days until wound closure was achieved.

CLINICAL CASE

A 48-year-old male, obese, with type 2 diabetes mellitus undergoing treatment with insulin, and history of intense tobacco use. Presented to the emergency room with 8-day history of left inguinal swelling and local hyperthermia, associated with scrotal swelling, pain, and purulent discharge. He previously had consulted with a general practitioner who administered an unspecified intramuscular antibiotic to which he presented no improvement.

On clinical examination, he had fever with a temperature of 38.6°C (101.5°F). Left inguinal swelling with local hyperthermia, redness, and purulent discharge. On laboratory analysis the results were leukocytosis (22.4 x 10³/ μL), neutrophilia (19.4 x 10³/ μL), hemoglobin of 15.3 g/dL, 266,000 platelets, glucose of 280 g/dL, creatinine 1.0 mg/dL.

Fluid resuscitation and broad-spectrum antibiotics were initiated, following recommendation from the infectiology department.

He underwent emergency surgery, a transverse left inguinal incision was made, with a subsequent surgical debridement. The next day, a second surgical debridement and an extension of the transverse incision to the contralateral inguinal area, lower abdominal wall and scrotal raphe were also made. **Figure 1** Cultures were positive for *Escherichia coli*, *Streptococcus* and *Bacteroides* spp.

After multiple surgical debridements, on the 15th day of hospital stay cultures were negative therefore a partial wound closure was done. A VAC device was applied on the left inguinal wound with extension to the scrotum through the inguinal canal (**Figures 2A and 2B**).

During his hospital stay he received 25-day treatment with broad-spectrum antibiotics in accordance with the infectiology department recommendations. He underwent a total of 10 surgical debridements and four VAC device replacement every 4th day. Afterwards a closed drain was placed (**Figure 3**).

Upon discharge, the patient continued with oral antibiotic, and analgesic. The closed drain was withdrawn after 10 days, the surgical wound closed satisfactorily.

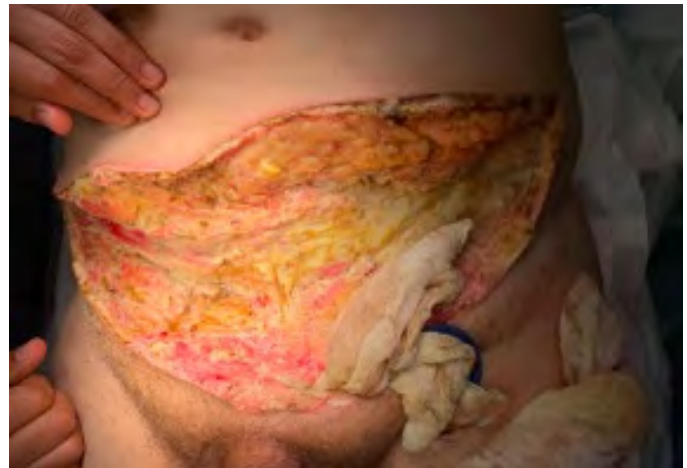

Figure 1
A transverse lower abdominal wall incision was made.

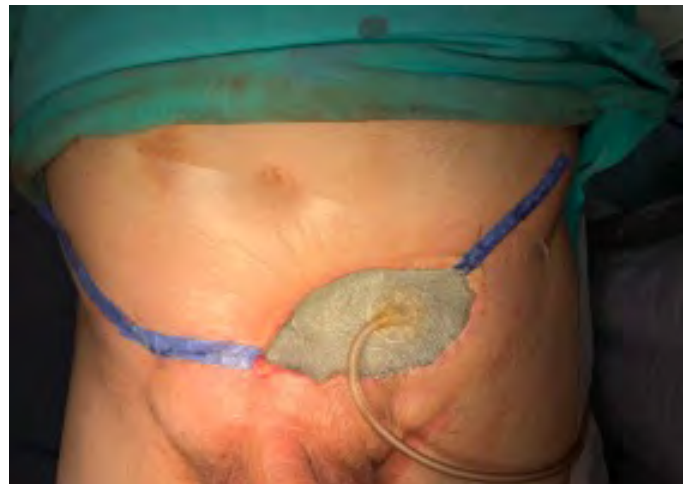

Figure 2A
VAC on the left inguinal wound with extension to the scrotum through the inguinal canal.

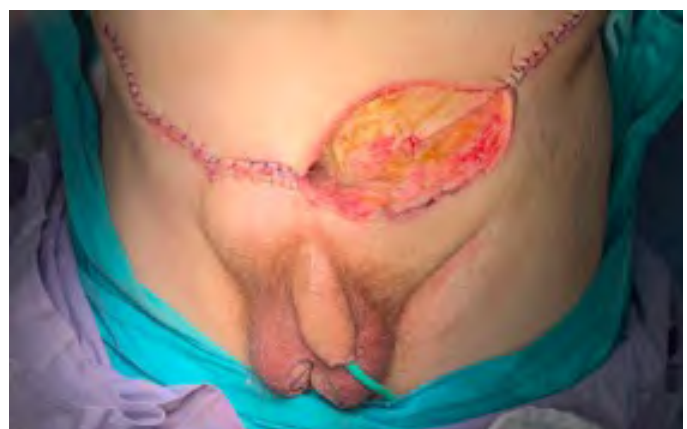


Figure 2B
VAC on the left inguinal wound with extension to the scrotum through the inguinal canal.

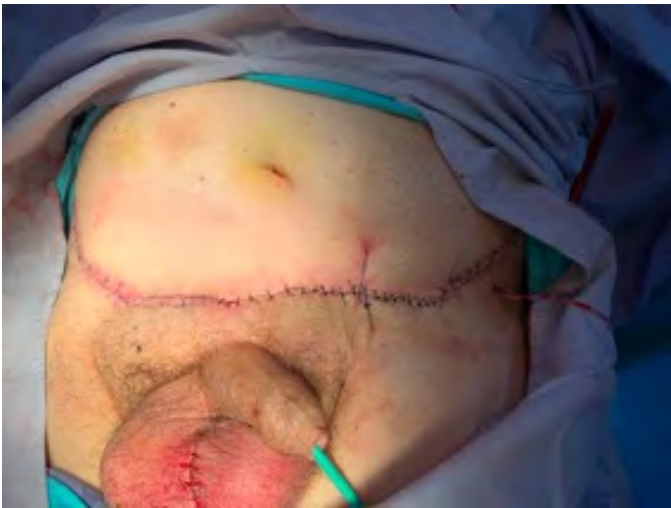

Figure 3

Postoperative picture after 10 surgical debridements and four VAC device replacement.

DISCUSSION

Fournier's Gangrene is a type I necrotizing fasciitis which affects the perineal and genital area, it has a predilection for the male gender with a relation of 10:1 over female gender, the age of presentation is around 50 years. It is characterized by obliterating endarteritis of subcutaneous arteries, resulting in subcutaneous tissue gangrene and subsequent gangrene of adjacent skin. The most common affected sites are the urethra, anorectal area, and cutaneous infections, with a high mortality of around 20 - 30%^{1,2,3,4}.

First described in 1883 by Jean Alfred Fournier in a series of 5 patients with a gangrene of the genital area (penis and scrotum) of idiopathic etiology, acute onset, and fulminant course^{1,2,3,5}. Due to the clinic presentation, it was Willison who coined the term "necrotizing fasciitis"⁶.

Associated risk factors are diabetes mellitus (20-70% of patients), history of alcohol misuse, obesity, genital trauma, genitourinary infection, HIV infection, malnutrition, old age, peripheral vascular disease, steroid chronic use, or any kind of immunosuppression^{1,2,3,4,5}.

It generally presents as polymicrobial etiology, caused by three or more microorganisms, the most frequent being: *Escherichia coli* (48%), *Enterococcus* (28%), *Proteus* and *Anaerobes*, being *Bacteroides fragilis* the most frequent of the latter. On the other hand, in a retrospective study conducted in the United States, different results were observed, with *Staphylococcus* being the most frequent (46%), followed by *Streptococcus* (37%), *Bacteroides* (24%), *Candida* (22%), and *Escherichia coli* (20%)⁷. However, not all the causal agents can be isolated in cultures^{1,2,3,4}. Previously, it was considered an entity of idiopathic etiology, however today it is known that only a quarter of patients belong to this group⁶.

Based on the microorganisms involved, necrotizing fasciitis can be divided into four types: type I or polymicrobial (55-80%), type II or monomicrobial (10-15%), type 3 (*Clostridium*) and type 4 or fungal⁶.

Clinically four phases can be distinguished in the necrotizing fasciitis: the first phase (24 - 48 hours) with non-specific symptoms such as edema, erythema and itching of the affected area, the second phase or invasive phase is brief, with the presence of regional manifestations of inflammation, the third phase characterized by necrosis that can spread to the anterior abdominal wall, armpit or thighs, clinical decline and even progression to septic shock. Finally, the fourth phase or spontaneous restoration with the presence of granulation tissue and epithelization during the following months².

Early diagnosis is crucial and aggressive surgical treatment in the first 24 hours are necessary to attain the best results, considering the reported speed of gangrenous area spread which is 2-3 cm/hour or 1 inch/hour. Clinically, local and systemic symptoms are distinguished, including: perianal and perineum pain, pruritus, edema, erythema, fever, tachycardia and chills^{1,2,5,6}. There must be a high index of suspicion since the time elapsed between the onset of symptoms and gangrene is 5.1 ± 3.1 days⁸. Computed tomography is the first choice study with a reported sensitivity of 88.5% and specificity of 93.3%. Ultrasound can show subcutaneous emphysema and inflammation and can be useful to rule out other pathologies (inguinal hernia, orchitis, testicular torsion, etc.), radiography is not useful in this pathology⁸.

There are prognostic scoring systems that can predict clinical outcomes and death. Such as the Fournier's Gangrene Severity Index (FGSI) in which a score greater than 9 suggests a 75% probability of death. There is low risk of progression of the infectious stage if the measurement of the affected area is < 3% and is increased if the area is > 5%^{2,4,5}.

The management is focused on three strategies: initial resuscitation, empiric broad-spectrum antibiotic coverage (covering gram-positive and negative, and anaerobes), and aggressive surgical intervention. Antibiotic triple therapy with penicillin, metronidazole, or clindamycin (for anaerobes), and third-generation cephalosporin with aminoglycosides (for gram negatives) is recommended. Vancomycin or linezolid should be added when methicillin-resistant *Staphylococcus aureus* (MRSA) infection is suspected. Multiple surgical debridements are usually required with an average of 3.5 debridements reported in the literature. The resulting surgical wound may be closed by secondary intention^{1,2,3,4}.

Among the current therapeutic strategies used to manage the closure of the wound is the use of VAC therapy. A therapy used since 1995 for wound closure, it consists of exposing the wound to sub-atmospheric pressures to promote fibroblast migration, greater perfusion, and cell proliferation, aiding in the closure reducing the size of the wound surface area, which in turn achieves a decrease in the frequency of dressing changes, and the hospital stay^{1,2,4,9}. Another advantage is that this therapy can act as a temporary closure method to prepare for reconstruction in patients with very large skin defects⁸.

Due to the large skin defects that can result from this process, it is not uncommon for the plastic surgery service to be involved in the subsequent reconstruction. Among the surgical methods that can be used are skin grafts, local advancement flaps, scrotal, fasciocutaneous or myocutaneous flaps, and testicular transposition. The size, location and depth of the defect must be assessed in order to choose the most appropriate reconstruction method, with the aim

of covering the defect while preserving the function with adequate aesthetic results^{10,11}.

CONCLUSIONS

Necrotizing fasciitis is an emergency that requires early surgical intervention immediately upon diagnosis, as well as multidisciplinary treatment that may allow prompt recovery, and return to a normal lifestyle. One of the most important risk factors is the presence of Diabetes Mellitus. This entity has a high mortality, so early recognition that allows therapeutic intervention is of the utmost importance.

BIBLIOGRAPHY

1. Iacovelli V, Cipriani C, Sandri M, Filippone R, Ferracci A, Micali S, et al. The role of vacuum-assisted closure (VAC) therapy in the management of FOURNIER'S gangrene: a retrospective multi-institutional cohort study. *World J Urol.* 2021 Jan 1;39(1):121-8.
2. Shyam DC, Rapsang AG. Fournier's gangrene. *The Surgeon* (2013): 1-11. <http://dx.doi.org/10.1016/j.surge.2013.02.001>
3. AlShehri, YA., AlBurshaid, H, AlBassam L, & AlMutairi K. Management of Fournier's gangrene with skin grafting by bagging technique of testes: case report. *GMS Interdisciplinary plastic and reconstructive surgery DGPM.* 2019; 8:1-3. <https://doi.org/10.3205/iprs000128>
4. Singh A, Ahmed K, Aydin A, Khan MS, & Dasgupta P. Fournier's gangrene. A clinical review. *Archivio Italiano Di Urologia e Andrologia.* 2016;88(3): 157-164. <https://doi.org/10.4081/aiua.2016.3.157>
5. Joury A, Mahendra A, Alshehri M, & Downing, A. Extensive necrotizing fasciitis from Fournier's gangrene. *Urology Case Reports.* 2019;26,100943:1-3. <https://doi.org/10.1016/j.eucr.2019.100943>
6. Zhang KF, Shi CX, Chen SY, Wei W. Progress in Multidisciplinary Treatment of Fournier's Gangrene. *Infection and Drug Resistant.* 2022; 15: 6869-6880. <https://doi.org/10.2147/IDR.S390008>
7. Castillejo Becerra CM, Jaeger CD, Rose JR, et al. Microorganisms and antibiogram patterns in Fournier's Gangrene: contemporary experience from a single tertiary care center. *J Urol.* 2020;204(6):1249-1255. doi:10.1097/JU.0000000000001194
8. Montrief T, Long B, Koyfman A, et al. Fournier Gangrene: a review for emergency clinicians. *J Emerg Med.* 2019;57(4):488-500. doi:10.1016/j.jemermed.2019.06.023
9. Syllaio A, Davakis S, Karydakis L, et al. Treatment of Fournier's Gangrene with vacuum-assisted closure therapy as enhanced recovery treatment modality. *In Vivo.* 2020;34(3):1499-1502.
10. Insua-Pereira I, Ferreira PC, Teixeira S, et al. Fournier's gangrene: a review of reconstructive options. *Cent European J Urol.* 2020;73(1):74-79.
11. Sandberg JM, Warner HL, Flynn KJ, et al. Favorable outcomes with early component separation, primary closure of necrotizing soft tissue infections of the genitalia (Fournier's Gangrene) debridement wound defects. *Urology.* 2022;166:250-256.